



PATIENT

Winnie Diehl

SPECIES

Canine

BREED

Golden Retriever

SEX

Female Spayed

AGE

5 years

WEIGHT

78lbs

INTERPRETED BY

Maggie Machen Lamy,
DVM, DACVIM
(Cardiology)

IMAGING PERFORMED BY

Jennifer Todd, DVM

HOSPITAL NAME

Lambs Gap Animal
Hospital

REFERRING VET

Dr. Todd

INVOICE

22206

DATE

11/30/21

PRESENTING CLINICAL SIGNS

History: New grade I-II/VI left apical murmur. She was presented for lameness on 7/26/21 and 8/6/21 and orthopedic referral was advised. The exam and diagnostics performed prior to surgery at the specialist revealed a grade II/VI systolic murmur, possible main pulmonary artery enlargement on radiographs of the thorax. 4DX was negative on 8/6/21. pressure today was 163/96, 156/93, 154/89mmHg.

ELECTROCARDIOGRAPHIC FINDINGS *Note: Single lead ECGs are evaluated as a rhythm strip. Morphology/MEA cannot be definitively commented on.

A single lead ECG is available; 25mm/s, 10mm/mV. The average heart rate is 130bpm (range 115-150bpm). The rhythm is sinus in origin, with a p for every QRS complex and vice versa. The P and QRS morphologies are positive. No ectopic beats, pauses or other dysrhythmias observed. ECG diagnosis: Normal sinus rhythm with respiratory variation.

ECHOCARDIOGRAM FINDINGS

2D, m-mode, color flow and doppler imaging is available. Minimal diffuse thickening of mitral valve leaflets with no obvious prolapse into the left atrial lumen. No mitral regurgitation is identified. Normal left atrial dimension. Normal LV diameter with adequate myocardial function. The tricuspid valve appears subjectively normal, with no tricuspid regurgitation. The right heart is normal (subjective). No overt evidence of pulmonary arterial hypertension. The pulmonic and aortic valves are normal in morphology and mobility. No aortic abnormalities identified, however the LVOT velocity is mildly elevated. Normal pulmonic outflow velocities. No aortic or pulmonic insufficiency. No pericardial or pleural effusion noted. No cardiac tumors observed.

CARDIAC CHART

CANINE CARDIAC PARAMETERS	MR VMAX (m/s)	TR VMAX (m/s)	LA/AO (Boon method)	LA/AO (Heart Base; Swe)	FS (%)	EF (%)	EPSS (cm)
NORMAL PARAMETER	4.5-5.5	<2.7	1.3	<1.6	28-40	40-100	<0.6
PATIENT	NA	NA	1.1	1.1	29	52	0.5
CANINE CARDIAC PARAMETERS	HR (BPM)	AV VMAX (m/s)	PV MAX (m/s)	BODY WEIGHT (kg)	LA 2D short axis Base view (cm)	LVIDd Avg; 2D and m-mode short axis (cm)	LVIDs Avg; 2D and m-mode short axis (cm)
NORMAL PARAMETER	50-100	0.7-1.7	0.7-1.6	BELOW	BELOW	BELOW	BELOW
PATIENT	NM	2.5	1.3	35.4	2.2	4.5	3.2
*Normal chamber parameters expressed as a mean value (SD)				3	1.27 (5.3)	2.46 (2.46)	1.36 (5.5)
BODY WEIGHT DEPENDENT PARAMETERS				5	1.40 (4.5)	2.74 (5.2)	1.60 (4.7)
<i>*Note: All measurements based upon multi-modal images and methods. An average value is reported.</i>				10	1.50 (3.8)	3.27 (3.5)	2.06 (3.1)
				15	1.83 (2.0)	3.71 (2.4)	2.43 (2.1)
				20	2.02 (1.9)	4.14 (2.2)	2.80 (2.0)
				25	2.18 (2.4)	4.48 (2.9)	3.10 (2.5)
				30	2.33 (3.3)	4.83 (3.9)	3.39 (3.4)
				35	2.48 (4.3)	5.17 (5.0)	3.69 (4.5)
				40	2.62 (5.2)	5.48 (6.1)	3.96 (5.4)
				50	2.88 (7.1)	6.07 (8.3)	4.46 (7.4)

Adapted from June Boon, Veterinary Echocardiography, 1998
Rishniw M and Hollis NE, J Vet Intern Med 2000; 14:429-435
Hansson et al, Vet Rad and Ultrasound 2002
Bonagura et al. Echocardiography: principles of interpretation, Vet Clin North Am 15:1177, 1995



PATIENT

Winnie Diehl

SPECIES

Canine

BREED

Golden Retriever

SEX

Female Spayed

AGE

5 years

WEIGHT

78lbs

INTERPRETED BY

Maggie Machen Lamy,
DVM, DACVIM
(Cardiology)

IMAGING PERFORMED BY

Jennifer Todd, DVM

HOSPITAL NAME

Lambs Gap Animal
Hospital

REFERRING VET

Dr. Todd

INVOICE

22206

DATE

11/30/21

INTERPRETATION OF THE FINDINGS & FURTHER RECOMMENDATIONS

The only cause of a murmur identified is increased flow velocity through the LVOT/aortic root. No obvious subaortic ridge or valvular abnormalities are visualized, and in the absence of structural abnormalities this is considered a benign flow murmur. If this is a new murmur, it is reasonable to monitor periodically via recheck echocardiography in the future. Additionally screening for fluid status abnormalities (dehydration, anemia, etc.) is recommended through routine lab work as these abnormalities would make this finding more prevalent. No significant valvular insufficiencies were noted, and no structural issues identified. The ECG is unremarkable, with a normal sinus rhythm.

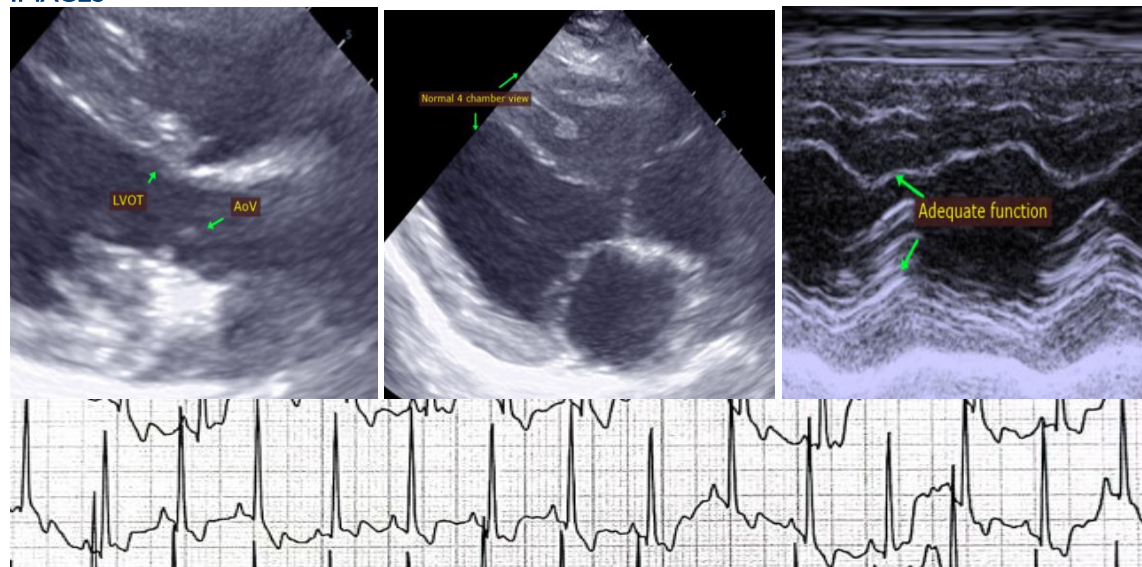
As an aside, avoid non-traditional diets in this breed lifelong.

No cardiac medications are indicated. No cardiac contraindication for general anesthesia.

Monitor for any development of cough, labored breathing or exercise intolerance.

Recommend recheck echocardiogram in 12-18 months to screen for progression or development of concurrent cardiac disease that the preexisting murmur may mask.

IMAGES



The information and recommendations provided are based on the images presented by the referring veterinarian. No evaluation can be communicated regarding pathology that was not visible in the image/video clips provided.

Thank you for this referral. This report was generated using transcription software, and minor dictation errors may be present. If the clinical or image interpretation does not parallel your findings or if I can be of any further assistance, please contact me.

Maggie Machen Lamy, DVM
Diplomate of the American College of Veterinary Internal Medicine (Cardiology)
info@sonopath.com